

Automatic detection Non-proliferative Diabetic Retinopathy using image processing techniques

RajuS. Maher¹, Dr. Mukta Dhopeswarkar²

¹Research Scholar Department of Computer Science & IT, Dr. Babasaheb Ambedkar Marathwada University, Aurangabad, India

²Assistant Professor Department of Computer Science & IT, Dr. Babasaheb Ambedkar Marathwada University, Aurangabad, India

ABSTRACT

Diabetes is a chronic disease that is reaching epidemic proportions worldwide. There are currently more than 190 million people with diabetes worldwide. The World Health Organization (WHO) estimates that this will rise to 221 million by the year 2010, largely due to population growth, ageing, urbanization and a sedentary lifestyle. Diabetes is currently the fourth main cause of death in most developed countries. In Singapore, the prevalence of diabetes in our population is 8.2% according to the 2004 National Health Survey. This is expected to grow as our population age.

Diabetic Retinopathy, if not well managed and controlled, can progress steadily to devastating complications like blindness. At present, various analyses on complicated interaction between hereditary and environmental factors are being undertaken regarding the onset of diabetes. The development of diabetic complication has become a major concern regarding the prognosis of diabetic patients.

Diabetes Retinopathy is one of the most common diseases that people get affected by over the years. By doing this paper, we hope to detect the stages of Diabetic Retinopathy as early as possible so as to prevent and cure more Singaporeans from falling prey to this disease

Keywords: Diabetes Retinopathy, World Health Organization (WHO), fundus Images.

I. INTRODUCTION

Diabetic retinopathy is a vascular disorder occurring due to the combination of micro-vascular leakage and micro-vascular occlusion within the retina. It is primarily classified into Non-Proliferative Diabetic Retinopathy (NPDR) and Proliferative Diabetic Retinopathy (PDR) [1]. It is a major public health problem and diabetic-related eye diseases are the commonest cause of vision defects and blindness in the world. The appearance of microaneurysms, hemorrhages and exudates represent to certain extent the degree of severity of the disease. Typically there are no salient symptoms in the early stages of diabetic retinopathy, but the number and severity predominantly increase with the time. Non proliferative diabetic retinopathy is the most common and may arise at any point in time after the onset of diabetes. Ophthalmologists detect these changes by examining the patient's retina and look for spots of bleeding, lipid exudation, or areas of retinal swelling [1][2]. Many techniques have been employed to perform exudates detection. A complete comparative analysis of the most recent techniques is made on [2]. Identification and recording of the following abnormalities (see Figure 1.1) will aid in the accurate assessment of retinopathy severity

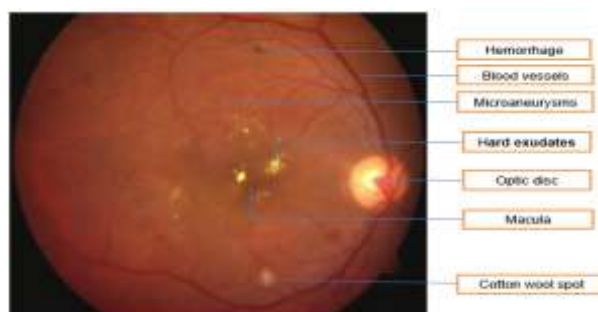


Fig. 1.1: Anatomical and pathological features in colour retinal image [1].

Microaneurysms: These are the earliest clinical abnormality to be noticed in the eye. These are local swelling of retina capillary and usually appear in isolation or in clusters. Their size ranges from 10 to 100 microns and are dark red spots that look like tiny hemorrhages. The number of microaneurysms increases as the degree of retinal involvement progresses [3].

Hemorrhages: Intra-retinal hemorrhages appear when capillaries or microaneurysms rupture and some blood leaks out of these vessels. In Figure 1.1 hemorrhages can be seen as red flame shaped regions

Hard exudates: Hard exudates represent leak of fluid that is rich in fat and protein from surrounding capillaries and microaneurysms within the retina. These are one of the main characteristics of diabetic retinopathy and appear as random yellowish patches of varying sizes, and shapes.

Soft exudates: These are often called cotton wool spots and are more often seen in advanced retinopathy. These abnormalities usually appear as little fluffy round or oval areas in the retina with a whitish colour, usually adjacent to an area of hemorrhage. Cotton wool spots come about due to the swelling of the surface layer of the retina in the absence of normal blood flow through the retinal vessels. The nerve fibers are injured in a particular location resulting in swelling and appearance of a cotton wool spot [3]. Proliferative diabetic retinopathy, the advanced stage retinopathy develops in more than 50 percent cases after about 25 years of onset of the disease. Therefore, it is more common in patients with juvenile onset diabetes. The hallmark of PDR is the growth of new blood vessels in the areas where normal capillaries have already closed. These new blood vessels are abnormal and fragile. They grow along the retina and along the surface of the clear, vitreous gel that fills the inside of the eye. By themselves, these blood vessels do not cause symptoms or vision loss. However, they have thin, fragile walls that leak blood resulting in severe vision loss and even blindness can be the end result. early screening and identification of patients with diabetic retinopathy will help to prevent loss of vision. Therefore an automated detection and treatment of diabetic retinopathy in an early stage can prevent the blindness [4]. Diabetes Retinopathy in simple words is damage to the blood vessels in the retina. A retina is a light sensitive tissue at the back of the eye. A healthy retina is required for good vision. It is caused when blood vessels swell and leak fluid and abnormal blood vessels are formed on the surface of the retina. Diabetic Retinopathy is not easily noticed at first but overtime the condition gets worst and even cause vision loss. Diabetic Retinopathy is said to affect both eyes. In my project, this disease is classified into 3 stages. The three stages are normal, non-proliferative Diabetic Retinopathy (NPDR), and Proliferative Diabetic Retinopathy (PDR) as shown below. Figure (1.1) (b-d) shows the optical image of three stages of NPDR. They are mild Diabetic Retinopathy, moderate Diabetic Retinopathy, and severe Diabetic Retinopathy [4, 6].

1. Diabetic Retinopathy

Diabetic Retinopathy is a common complication of diabetes mellitus, characterized by macular edema and frequently accompanied by lipid exudation. Diabetic Retinopathy, defined as retinopathy within

one disc diameter of the center of the macula is the major cause of vision loss. One of the morphological characteristics of diabetic retinopathy clinical signs is the onset of retinal hard exudates, which are manifested as whitish- yellowish changes. They are most frequently localized in the area of the macular region, surrounding the zones of retinal edema, although they can also be noticed in other localizations at the posterior pole of the eye fundus. They are a dominant feature in both exudative and mixed types of diabetic maculopathy. If they are very apparent and affect the center of macular region called fovea centralis, visual function is significantly and irrevocably damaged as shown in Figure 2.1. Diabetic maculopathy comprises of two aspects: First is the macular edema in which fluid and lipoproteins accumulate within the retina. Second is the macular ischaemia in which there is closure of perifoveal capillaries demonstrable on fundus fluorescein angiography. It is not known to what extent macular ischaemia contributes to the visual loss attributable to diabetic maculopathy and this work is limited to the automatic detection of macular edema and its severity stages.




Fig. 2.1: Normal vision (left) and same scene viewed by person with diabetic retinopathy (right)
[Courtesy: <http://www.nei.nih.gov>].

2. Non-Proliferative Diabetic Retinopathy

This color retinal photograph demonstrates non-proliferative diabetic retinopathy. The image is centered on the macula (the part of the retina responsible for central fine vision) with part of the optic nerve seen on the left of the photo (left eye). There are hemorrhages within the retinal tissue on the right side of the photograph. (Click image for full size image.) The doctor looks for small spots of bleeding or areas of retinal swelling due to fluid leakage. Sometimes, fatty material leaks from damaged vessels and collects in the retina as deposits called exudates. The ophthalmologist will often take color photos of the back of the eye to document the retinal changes. Non-proliferative diabetic retinopathy is further sub-divided into mild, moderate, and severe depending on the number and amounts of bleeding and leaking areas. Frequently, especially if there is reduced vision, the ophthalmologist may elect to investigate the retinal changes further with a special diagnostic test known as a fluorescein angiogram. This test involves injecting a yellow dye into an arm vein and photographing the back of the eye as the dye passes through the retinal

circulation. This test is especially useful for identifying areas of blood vessel damage and abnormal leakage from them. The test does not involve the use of X-rays. Patients should be aware that their urine will be bright yellow for a day or two following the injection. Fluorescein angiogram of the same patient shown above. The retinal vessels are filled with the fluorescent dye. Hemorrhages appear as dark spots in the angiogram and correspond to those seen in the color photo. On the right side of the image, there is damage to retinal blood vessels which no longer fill with the dye. This is called an area of non-perfusion, also called retinal ischemia. Optical Coherence Tomography (OCT) is another test that is commonly obtained in order to assess fluid accumulation (macular edema) in the retina in patients with diabetes. OCT can demonstrate areas of retinal thickening and can be a useful tool in assessing a patient's response to a treatment. Proliferative diabetic retinopathy (PDR) is a more advanced form of diabetic retinopathy and a major cause of visual loss in diabetic patients. Patients at risk for this complication require frequent eye exams and often immediate treatment once the disorder is recognized. As retinal blood vessels become damaged and close off in diabetic retinopathy due to the cumulative effects of diabetes, the peripheral portions of the retinal circulation begin to close down causing the retina to become oxygen deficient or ischemic. This process is known as retinal ischemia and is believed to be the first step in the development of proliferative diabetic retinopathy. Presumably, the ischemic (nutrient-starved) retina releases a chemical message or growth factor which leads to the growth of new abnormal blood vessels (neovascularization) in the eye. These abnormal vessels often grow on the surface of the retina, at the optic nerve, or in the front of the eye on the iris.

Color retinal photograph centered on the optic nerve (left eye). This picture demonstrates proliferative diabetic retinopathy. Abnormal vessels (neovascularization) are growing from the nerve over the retinal surface and into the vitreous jelly (the clear substance which fills the eye).

3. Drawing of Proliferative Diabetic Retinopathy

Unfortunately, neovascularization is never good for the eye. The new vessels cannot replace the flow of necessary nutrients and, instead, can cause many problems such as vitreous hemorrhage (bleeding into the gel which fills the eye), traction retinal detachment, and uncontrolled glaucoma (high pressure in the eye). These problems occur because new vessels are fragile and are prone to bleed. As they grow within the eye associated scar tissue may exert traction on adjacent structures. This pulling may produce a distortion of the retina and even lead to a retinal detachment. When the vessels grow in the

front of the eye on the colored iris (iris neovascularization) they can clog the fluid outflow channels and cause the pressure in the eye to become very high. This is called neovascular or rubeotic glaucoma. Color retinal photograph centered on the optic nerve (left eye). This picture demonstrates proliferative diabetic retinopathy. Abnormal vessels (neovascularization) are growing from the nerve over the retinal surface and into the vitreous gel. Some of these vessels have bled into the vitreous (vitreous hemorrhage). Color retinal photograph centered on the optic nerve (left eye)[5]. This picture demonstrates proliferative diabetic retinopathy. Abnormal vessels (neovascularization) are growing from the nerve over the retinal surface and into the vitreous gel. Some of these vessels have bled into the vitreous (vitreous hemorrhage). Color retinal photograph demonstrating severe proliferative diabetic retinopathy. Abnormal vessels (neovascularization) are growing from the nerve over the retinal surface producing a fractional retinal detachment. In advanced cases of proliferative diabetic retinopathy such as this, a surgical treatment known as a vitrectomy may be required to flatten the retina. Oftentimes these abnormal blood vessels will grow and the patient will have no symptoms and normal vision. However, these blood vessels are very fragile and can suddenly break open and bleed. When these blood vessels bleed, blood spills out into the normally clear vitreous gel that fills the central hollow part of the eye. This can result in a rapid and sudden decrease in vision. This type of bleeding is termed a Vitreous Hemorrhage. The change in vision from a vitreous hemorrhage can run the spectrum from a few floaters, to cobwebs, to cloudy vision, or to complete loss of vision. Like a bruise, a Vitreous Hemorrhage will usually be absorbed by the body over the course of several weeks to months, resulting in some improvement in vision. However, sometimes the blood does not clear on its own and surgery is necessary to remove the blood-filled vitreous gel. This surgery is called a Vitrectomy and will be described in a later section. If caught in its early stages, proliferative diabetic retinopathy can sometimes be arrested with pan retinal photocoagulation or the injection of an off-label medication into the eye.

II. IMAGE DATABASE AND PREPROCESSING

The digital colour retinal images required for the development of automatic system for retinopathy detection are provided by the Department of Ophthalmology, Kasturba Medical College (KMC), and Manipal. The images are captured by a Zeiss FF 450IR fundus camera (Figure 3.1). A modified digital backunit (Sony 3CCD colour video camera) is connected to the fundus camera to convert the fundus

image into a digital image. The digital images are processed and saved on the hard drive of a Windows based computer with a resolution of 768 x 576 in 24 bit JPEG format. This consists of 8-bits of Red, Green and Blue (RGB) layers with 256 levels each. The images are linked to the patient data using the Visupac software, which is a patient database [4]. The images are usually obtained from the posterior pole's view including the optic disc and macula. A total of over 300 images are captured by the ophthalmologists. Out of those images only 148 images are considered for testing the system after consulting with the expert ophthalmologist. Images of the patients treated by laser are not considered in the work [6][9][10][11].

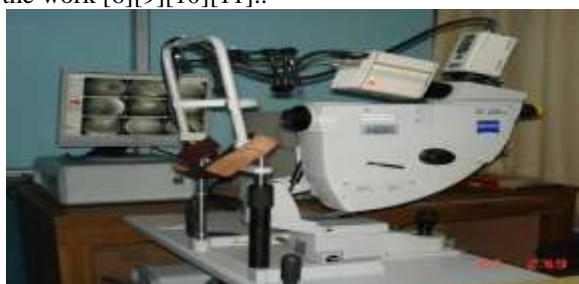

Fig.3.1 Zeiss FF 450IR fundus camera.

Apart from the KMC database, two publicly available retinal databases called DRIVE and STARE are used for testing the retinal vessel segmentation method and DIARETDB1 standard database is used for testing exudate detection method. The details of these databases are as follows. The STARE Database: There are twenty retinal fundus slides and their ground truth images in the STARE (Structured Analysis of Retina) database. The images are digitized slides captured by a TopCon TRV-50 fundus camera with 35 degree field of view. Each slide was digitized to produce a 605 x 700 pixel image with 24-bits per pixel. All the twenty images were carefully labeled by hand to produce ground truth vessel segmentation by an expert. Figure 3.2 shows an example of an image from the database. The DRIVE Database: The second image database is referred as the DRIVE (Digital Retinal Images for Vessel Extraction). The database consists of 40 colour fundus photographs and their ground truth images [5] [7].

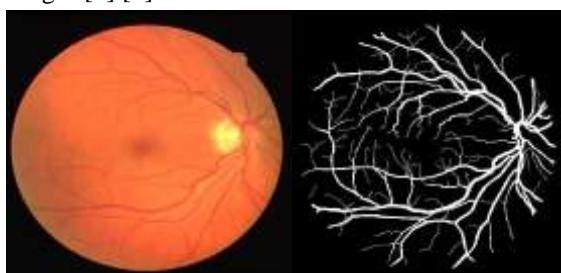


Fig. 3.2: Retinal image from STARE database (left), hand labeled ground truth vessel segmentation (right).

All images in DRIVE database are digitized using a Cannon CR5 non-mydratic 3CCD camera with a 45 degree field of view. Each image is captured using 24-bits per pixel at the image size of 565x584. These images were labeled by hand, to produce ground truth vessel segmentation and Figure 3.3 shows one such image [9][10][11].

1. Database

Database: The DAIRETDB1 database consists of 89 colour fundus images of which 84 contain at least mild non proliferative signs of the diabetic retinopathy (see Figure 3.4), and five are considered as normal which do not contain any signs of the diabetic retinopathy according to all the experts participated in the evaluation. Images were captured with the same 50 degree field-of-view digital fundus camera with varying imaging controlled by the system in the Kuopio university hospital, Finland. The image ground truth provided along with the database is based on expert selected findings related to the diabetic retinopathy and normal fundus structures. Special software was used to inspect the fundus images and annotate the findings as hard exudates, hemorrhages and microaneurysms [8][9][10][11].

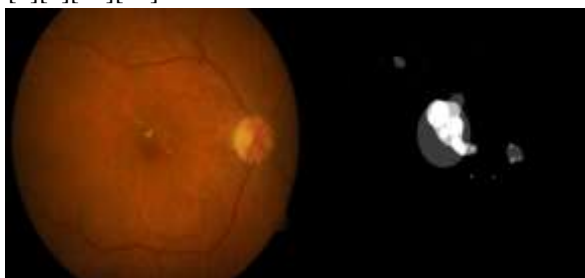


Fig. 3.4: Example of abnormal fundus image from DIARETDB1 database (left), and Ground truth of hard exudates (right).

2. Preprocessing

Patient movement, poor focus, bad positioning, reflections, inadequate illumination can cause a significant proportion of images to be of such poor quality as to interfere with analysis. In approximately 10% of the retinal images, artifacts are significant enough to impede human grading. Preprocessing of such images can ensure adequate level of success in the automated abnormality detection. In the retinal images there can be variations caused by the factors including differences in cameras, illumination, acquisition angle and retinal pigmentation. First step in the preprocessing is to attenuate such image variations by normalizing the colour of the original retinal image against a reference image. Few of the retinal images acquired using standard clinical protocols often exhibit low contrast. Also, retinal images typically have a higher contrast in the center of the image with reduced contrast moving outward

from the center. For such images, a local contrast enhancement method is applied as a second preprocessing step. Finally it is required to create a fundus mask for each image to facilitate segmentation of lesions and anatomical structures in later stages. The pre-processing steps are explained in detail in the following subsections [9][10].

3. Colour Normalization

Colour normalization is necessary due to the significant intra-image and inter-image variability in the colour of the retina in different patients. There can also be, differences in skin pigmentation, aging of the patient and iris colour between different patients that affect the colour of the retinal image. Colour normalization method is applied to make the images invariant with respect to the background pigmentation variation between individuals. The colour normalization is performed using histogram matching. In histogram matching a processed image can have a shape of the histogram as specified by the user. This is done by modifying the image values through a histogram transformation operator which maps a given initial intensity distribution into a desired distribution using the histogram equalization technique as an intermediate stage. Let $P_s(s)$ and $P_d(s)$ represent the standard image and desired image probability density functions, respectively.

4. Fundus Mask Detection

The mask is a binary image with the same resolution as that of fundus image whose positive pixels correspond to the foreground area. It is important to separate the fundus from its background so that the further processing is only performed for the fundus and not interfered by pixels belonging to the background. In a fundus mask, pixels belonging to the fundus are marked with ones and the background of the fundus with zeros. The fundus can be easily separated from the background by converting the original fundus image from the RGB to HSI colour system where a separate channel is used to represent the intensity values of the image. The intensity channel image is thresholded by a low threshold value as the background pixels are typically significantly darker than the fundus pixels. A median filter of size 5×5 is used to remove any noise from the created fundus mask and the edge pixels are removed by morphological erosion with a structuring element of size 5×5 . Figure 3.5 (b) shows the example of the fundus mask [9][10][11].

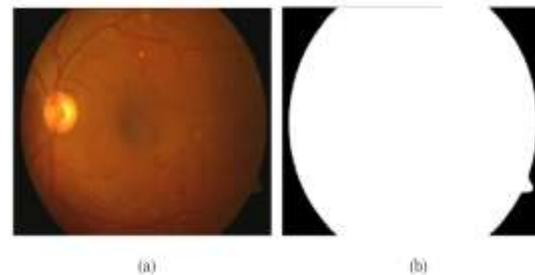


Fig. 3.5: Automatic fundus masks generation. (a) Input image; (b) Automatically generated fundus mask.

III. CONCLUSION

To develop an automatic retinal image processing system, the first important thing is to obtain an effective database. To realize this and also for facilitating comparison with the existing methods, four sets of Retinal databases are used. Details of the fundus camera and image properties of each of these databases are explained.

In any retinal image database, there will be some images with non-uniform illumination and poor contrast. There can also be difference in the colour of the fundus due to retinal pigmentation among different patients. These images are preprocessed before they can be subjected to anatomical and pathological structure detection. Colour normalization is performed to attenuate colour variations in the image by normalizing the colour of the original retinal image against a reference image. In order to correct non uniform illumination and to improve contrast of an image, contrast-limited adaptive histogram equalization is employed. On application of this method, the image quality is significantly improved with the increase in contrast. Each fundus camera has a mask of different shape and size according to its settings. By automatically detecting the fundus mask a lesion detection algorithm or vessel detection algorithm can process only the pixels of the fundus leaving out the background pixels. The following Chapters will explain the methods used to detect anatomical and pathological structures in retinal image leading to the development of automatic system for the identification of severity levels in diabetic maculopathy.

REFERENCES

- [1] Raju Maher, Sangramsing Kayte, Dr. Mukta D "Review of Automated Detection for Diabetes Retinopathy Using Fundus Images" *International Journal of Advanced Research in Computer Science and Software Engineering* Volume 5, Issue 3, March 2015.
- [2] RajuSahebrao Maher, Sangramsing N Kayte, Sandip T Meldhe and Mukta

- Dhopeshwarkar. Article: Automated Diagnosis Non-proliferative Diabetic Retinopathy in Fundus Images using Support Vector Machine. *International Journal of Computer Applications* 125(15):7-10, September 2015. Published by Foundation of Computer Science (FCS), NY, USA
- [3] Raju Maher, Sangramsing Kayte, Dnyaneshwar Panchal, PankajSathe, Sandip Meldhe " A Decision Support System for Automatic Screening of Non-Proliferative Diabetic Retinopathy" *International Journal of Emerging Research in Management &Technology* ISSN: 2278-9359 (Volume-4, Issue-10) October 2015
- [4] RajuSahebrao Maher, Dnyaneshwar S. Panchal, Sangramsing Kayte, Dr. Mukta Dhopeswarkar "Automatic Identification of Varies Stages of Diabetic Retinopathy Using Retinal Fundus Images"-*International Journal of Advanced Research in Computer Science and Software Engineering* Volume 5, Issue 9, September 2015 ISSN: 2277 128X
- [5] <http://www.nei.nih.gov/health/diabetic/retinopathy.asp>
- [6] Diabetic Retinopathy-Early Detection Using Image Processing Techniques
- [7] Diseases and Surgery of the Macula, Retina, and Vitreous Diabetic Eye Disease By John H. Drouilhet, M.D., FACS.
- [8] DIARETDB0: Evaluation Database and Methodology for Diabetic Retinopathy Algorithms
- [9] Sangramsing N. Kayte, Bharatratna P. Gaikwad, "Design and Development of Non-Proliferative Diabetic Retinopathy Detection Technique using Image Features Extraction Techniques "National Conference in Advances in computing (NCAC'13), 05-06 March 2013
- [10] Acharaya, U.R., Ng, E.Y.K., Tan, J.H., Sree, S.V. and Ng, K.H. (2012) An integrated index for the identification of diabetic retinopathy stages using texture parameters. *Journal of Medical Systems*, 36, 2011-2020.
- [11] Raju Maher, Charansing N. Kayte, "Automated Screening of Diabetic Retinopathy Using Image Processing", *IOSR Journal of Pharmacy and Biological Sciences*, Volume 10, Issue 6 Ver. III (Nov - Dec. 2015), PP 54-63.
- [12] Gonzalez, R.C. and Woods, R.E. (2008) *Digital image processing*. 3rd Edition, Prentice Hall, Upper Saddle River.
- [13] Andjelkovic, J., Zivic, N., Reljin, B., Celebic, V. and Sa-lom I. (2008) Application of multifractal analysis on medical images. *Wseas Transactions on Information Science and Applications*.